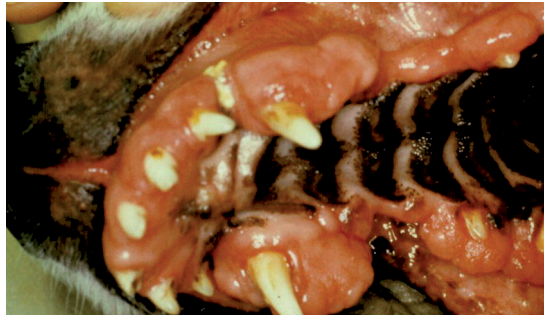


Proliferations/Neoplasia of the Oral Cavity in Dogs and Cats



Multiple Epulis in a Canine Oral Cavity

(With kind permission from Tierklinik Dres. Staudacher, Aachen-Brand)

Lesions in the oral cavity are seen quite frequent in both dogs and cats. From a clinical point of view it is of great importance to know if the lesions are caused by an infection or neoplasia. In this LABOKLIN Aktuell examples of both infectious and tumorous lesions in the oral cavity are described.

Eosinophil Ulcers

This disease is seen in cats and some dog breeds and belongs to the eosinophil granuloma complex. The lesions can be solitude or multiple. In dogs raised ulcerated plaques are most often seen, whereas cats show well-defined, ulcerated lesions with raised margins.

The aetiology is unclear, but the responsiveness to corticoids indicates an immune mediated pathogenesis.

Due to the unspecific clinical picture a histopathology examination is needed to determine the correct diagnosis. The results are characterized by the presence of eosinophil granulocytes as well as collagenolysis.

Plasmacytic Stomatitis

This disease affects cats, but rarely dogs, and presents itself with erythematous extensive proliferations. Histopathological it can be determined by a submucosal infiltration with plasma cells. The aetiology is thought to be immunological due to the increased immunoglobulin level in the blood. The Plasmacytic Stomatitis diagnose can only be differentiated from other lesions by histopathology.

Feline Ulcerative Stomatitis

This is seen in cats in the entire oral cavity but predominately in the deep throat and jaw angle. The aetiology is unclear. A microbial flora alteration is discussed as the cause, but for now it is believed that Feline Calici virus and Feline Herpes virus 1 are involved. The histopathology picture is non-specific but further examinations using PCR can be used in identifying the pathogen (see Fig. 1).

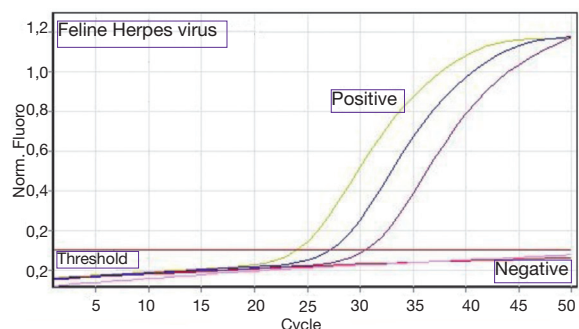


Fig. 1: Fluorescence curve Real-time-PCR

Besides infections also Neoplasia can cause proliferations and swellings. Tumours of the teeth (Odontoma, Cementoma) and the salivary glands will not be covered here.

Epulis

Epulis are considered to be hyperplasia and not neoplasia. The affected animals have rough, often multiple proliferations in their oral cavity.

Histopathological there are two forms: Epulis Fibromatosa and Epulis Ossificans, although mix-forms can occur. Both show connective

tissue proliferations. The Epulis Ossificans produces additional osteoid and well-differentiated trabeculae. The clinical picture is identical. Invasive growth is not known, but as a complete excision can be very difficult renewed growth can occur.

A macroscopic differentiation between Epulis and Canine Acanthomatous Ameloblastoma is not possible, so a histopathology exam is crucial.

Canine Acanthomatous Ameloblastoma

This is a tumour originated from the odontogenic epithelium (see Fig. 2) (Earlier: Acanthomatous Epulis). The histopathological exam is here particularly important in differentiating squamous cell carcinoma from ameloblastoma and epulis, as the ameloblastoma unlike the epulis show a local invasive growth but do not metastasize and therefore has a better prognosis than the squamous cell carcinoma.

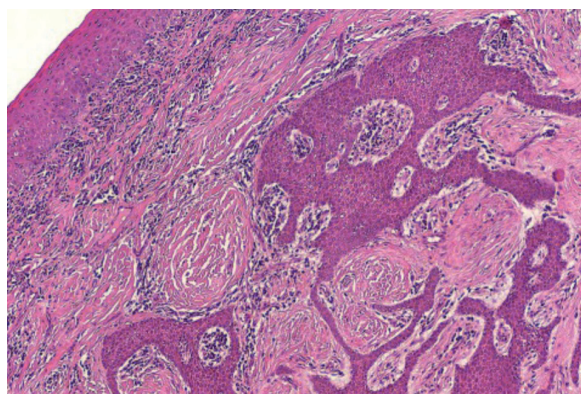


Fig. 2: Canine Acanthomatous Ameloblastoma with its odontogenic epithelia in the submucosa, HE, Obj x20

Papilloma

Papillomas are benign tumours originated from squamous epithelia. Macroscopic wart-like structures with a cauliflower-like surface are seen. There are two forms: In puppies and young dogs multiple viral papillomas can be seen which can spontaneous regress. The second form appears mostly in elderly dogs and with solitary lesions. Papilloma virae as cause for this form is controversial.

Prognosis is for both forms usually good, but in rare cases a malignant transformation can occur, with irregular deep epithelia taps showing in the histopathology preparation.

Squamous Cell Carcinoma

This is a malignant tumour form of the squamous epithelia cell. It is the most common tumour form in the feline oral cavity and the second common in the canine.

The tumour can invade both bone and soft tissue structures. The bigger the tumour is upon removal the poorer the prognosis.

In cats the tumours are macroscopical irregular red-grey colour lumps with a crumbly consistency. Often they ulcerate.

In dogs the tonsils but also the gingiva is affected.

Both local and remote metastases are described in dogs and cats.

Melanoma

Melanocytic tumours in the oral cavity are most often malignant. They are easily recognized by their black colour. The prognosis is poor, as early metastasis to the regional lymph nodes, lung, liver, kidney, brain and other organs often occur.

Fibrosarcoma

Fibrosarcomas are mesenchyme tumours originated from connective tissue. Macroscopical they are grey-red, rough proliferations. Fibrosarcomas are highly invasive leading to osteolysis complicating removal. Metastases can be seen in the lymph nodes and lungs.

Osteosarcoma

Bone distensions can be seen by osteosarcomas. The lytic and proliferating processes with bone remodelling can be difficult to distinguish from infectious or traumatic lesions – even histopathological. Often a diagnosis has to be made by a combination of clinical symptoms, images (e.g. x-rays) and histopathology lesions.

Conclusion

As many lesions of the oral cavity macroscopical have the same appearance a histopathology exam is recommended by every case. Prior to any resection, possible differential diagnosis should be considered in order to choose the most appropriate resection technique. Furthermore it is recommended to check the resection-lines histological to determine if all affected tissue has been thoroughly removed.